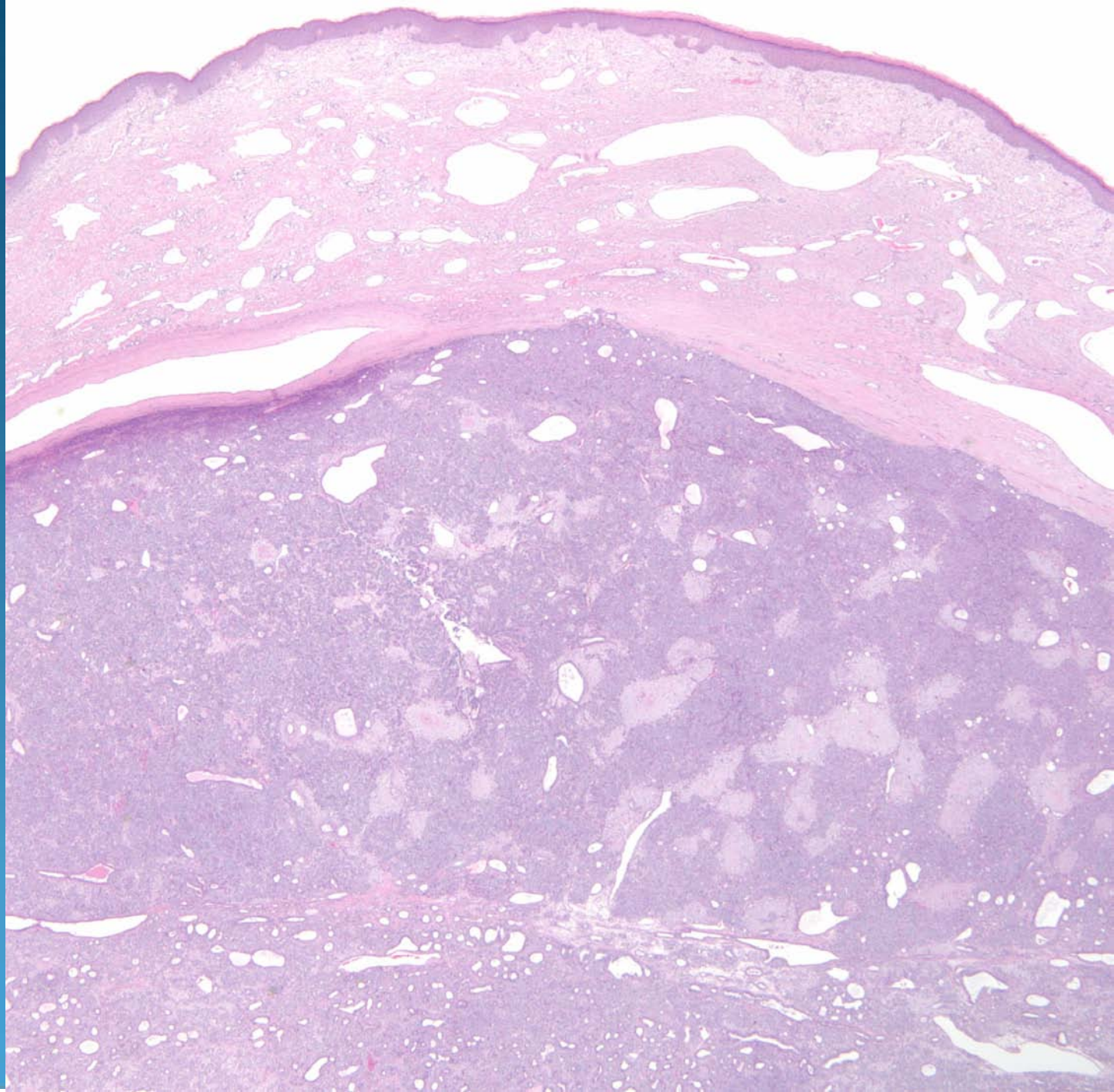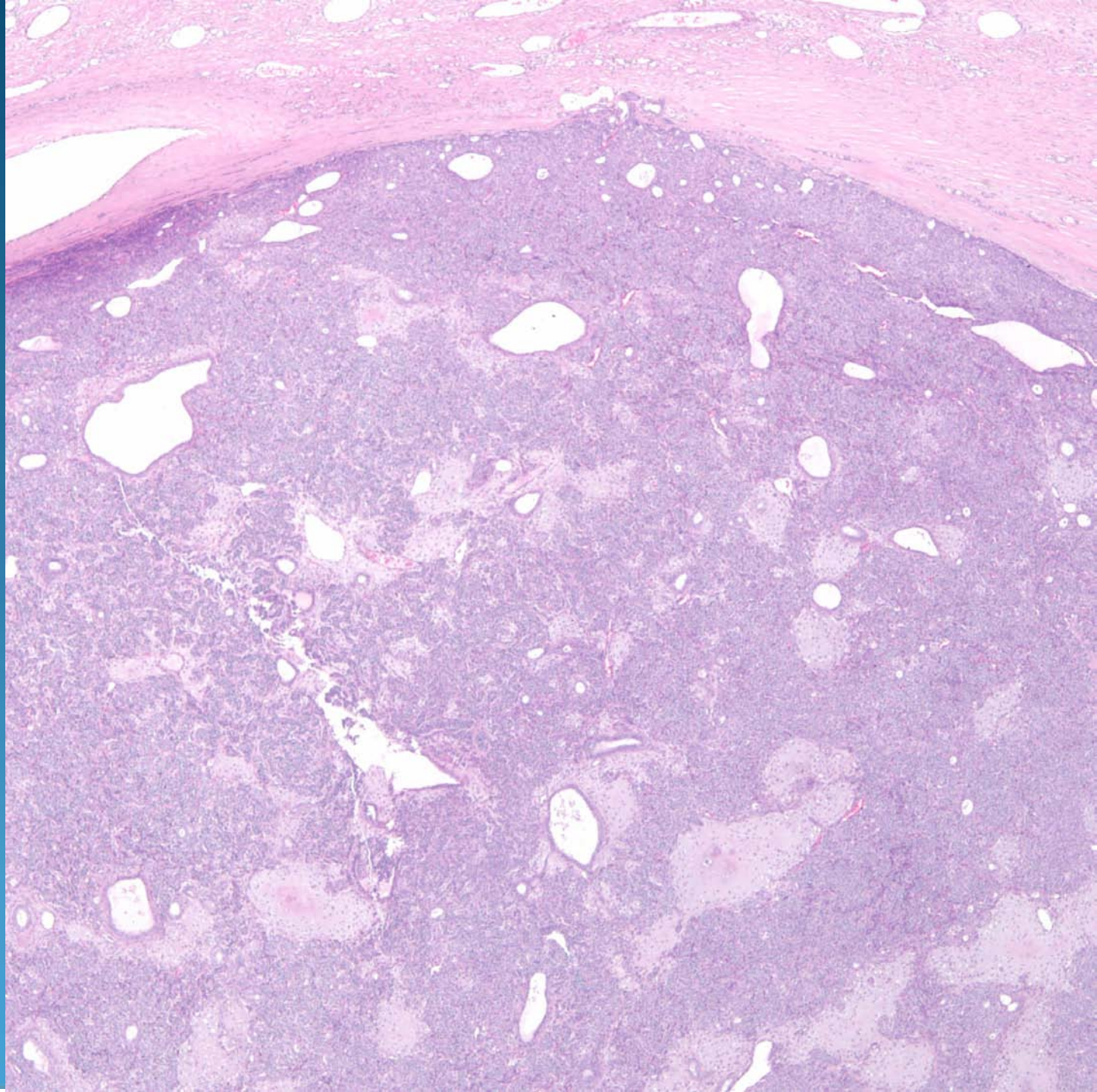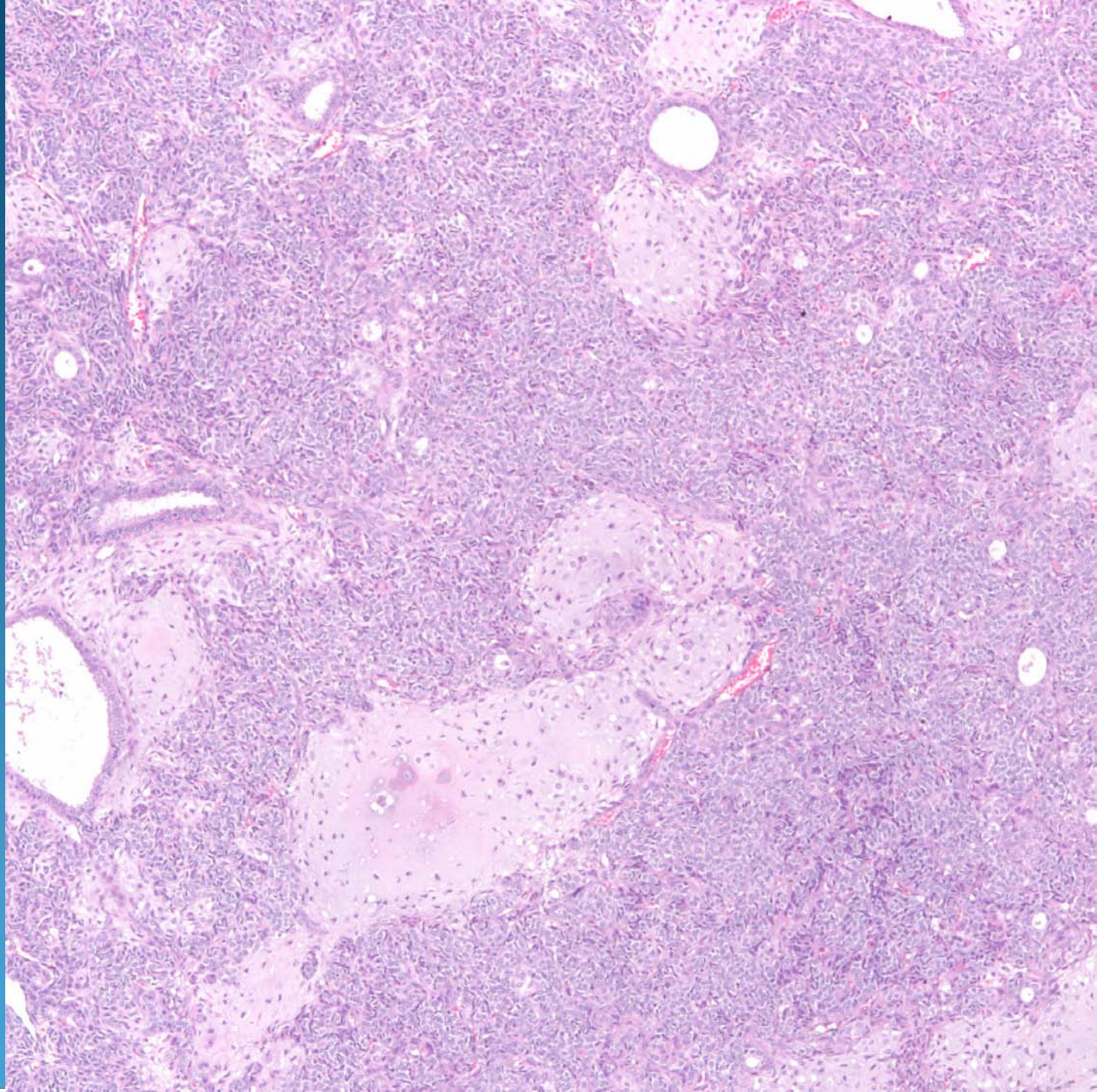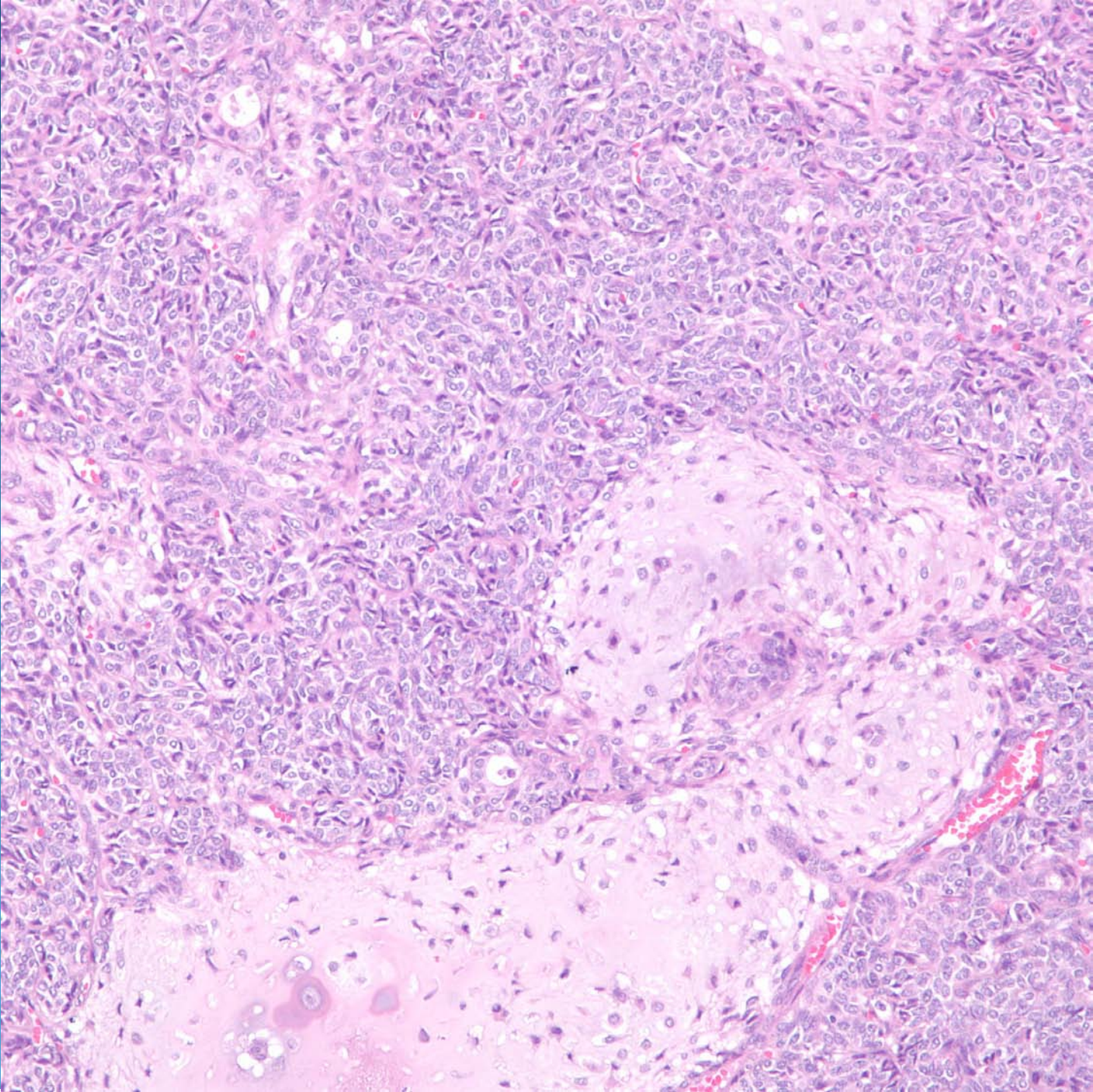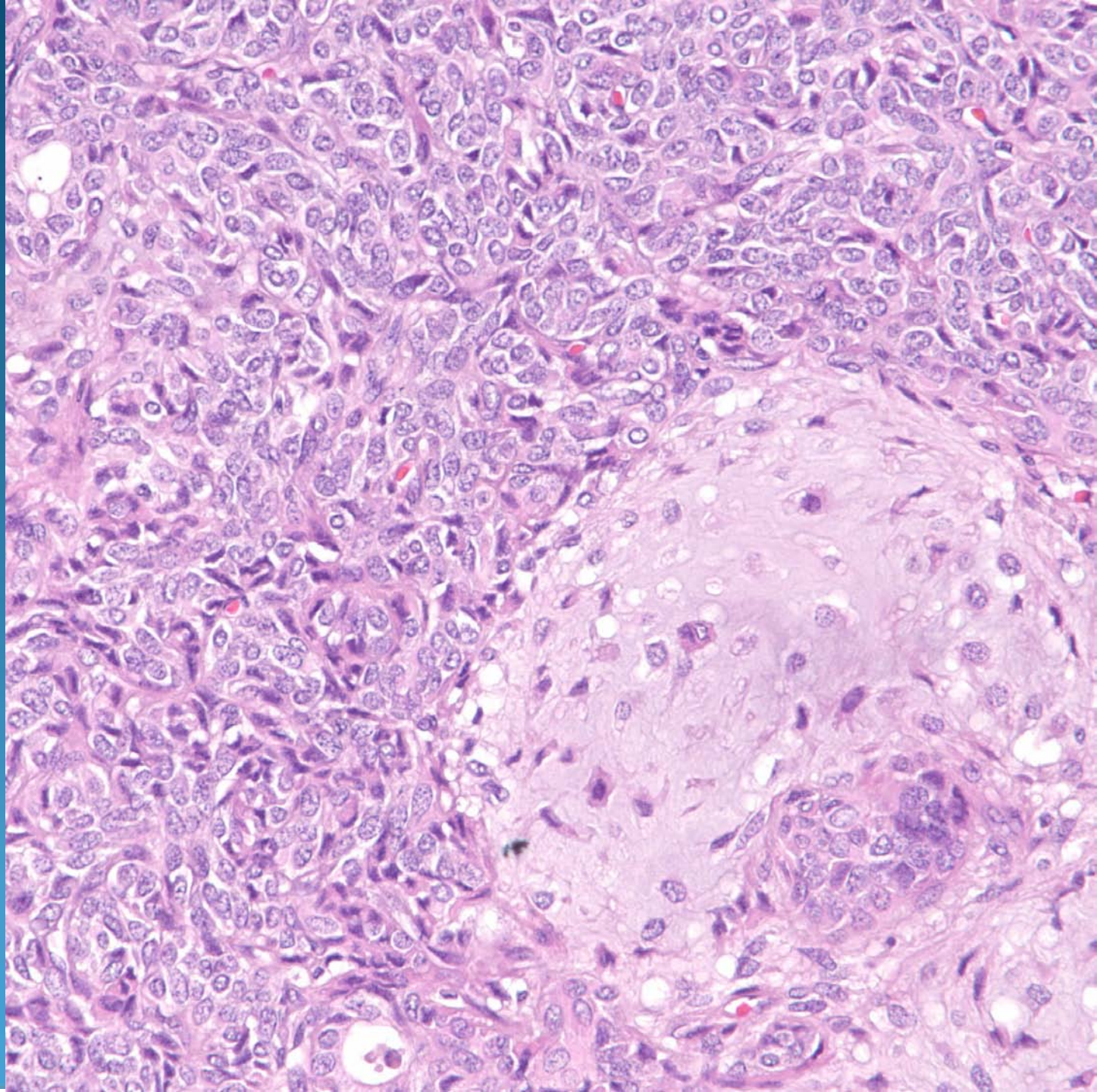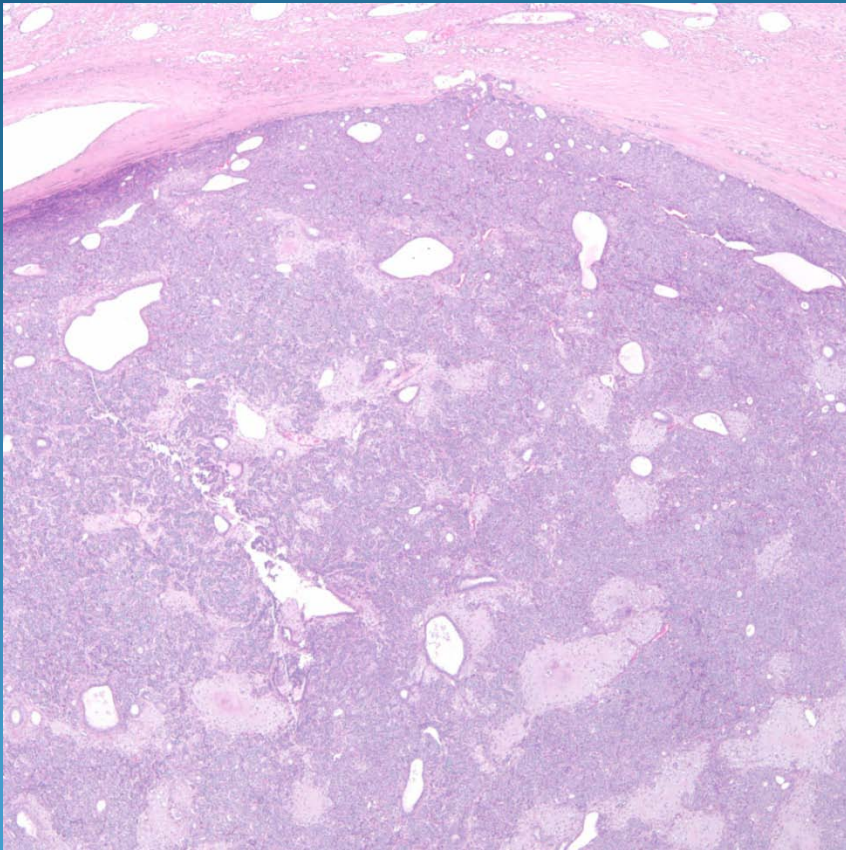


Chondroid Syringoma

(Benign Mixed Tumor of the Skin)

Pearls



- Circumscribed cellular tumor with solid areas mixed with cysts and ducts
- Look for mucin and cartilage